

Radiofrequency, High-Frequency, and Electrocautery Treatments vs Partial Inferior Turbinotomy

Microscopic and Macroscopic Effects on Nasal Mucosa

Francesco-Antonio Salzano, Professor; Renzo Mora, MD; Massimo Dellepiane, MD; Illias Zannis, MD; Giovanni Salzano, MD; Eva Moran, MD; Angelo Salami, Professor

Objective: To compare the microscopic and macroscopic effects of radiofrequency, high-frequency, and electrocautery therapies with partial inferior turbinotomy in the treatment of nasal obstruction caused by inferior turbinate hypertrophy.

Design: Nonrandomized controlled trial.

Setting: Department of Otolaryngology–Head and Neck Surgery, University of Genoa.

Patients: The study included 80 patients affected by nasal obstruction from hypertrophied inferior turbinates.

Interventions: Homogeneous patient groups A, B, C, and D underwent radiofrequency, high-frequency, and electrocautery treatments and partial inferior turbinotomy, respectively, to surgically reduce hypertrophied inferior turbinates.

Main Outcomes Measures: Prior to surgery and at 7-day and 2-month follow-up evaluations, patients' out-

comes were assessed via visual analogue scale, nasal endoscopy, nasal monofilament test, nasal mucociliary transport time (NMTT), anterior active rhinomanometry, and histologic examination of microbiopsy specimens from the inferior turbinate mucosa.

Results: Compared with groups A, B, and C 2 months after surgery, group D showed a lower subjective assessment of symptoms score, normal NMTT (vs an increase in all other groups), lower stimulus to trigger a touch response at monofilament test (vs hyposensitivity in the other groups), and absence of histologic changes.

Conclusions: To our knowledge, no one has previously performed comparative studies to conclusively demonstrate which surgical technique is ideal. Our results show that the partial inferior nasal turbinotomy is the best method of treatment because it most effectively maintains satisfactory nasal physiologic integrity without damaging nasal mucosa or underlying nerves.

Arch Otolaryngol Head Neck Surg. 2009;135(8):752-758

Author Affiliations:

Department of Otolaryngology–Head and Neck Surgery, University of Palermo, Palermo, Italy (Professor F.-A. Salzano); Departments of Otolaryngology–Head and Neck Surgery (Drs Mora, Dellepiane, and Zannis and Professor Salami) and Internal Medicine (Dr Moran), University of Genoa, Genoa, Italy; and University of Naples “Federico II,” Naples, Italy (Dr G. Salzano).

CHRONIC NASAL OBSTRUCTION is a common complaint often caused by hypertrophy of the inferior turbinates. Epidemiologic studies in European countries have shown that up to 20% of the population has chronic nasal obstruction caused by turbinate hypertrophy.¹ There are many causes of hypertrophic turbinate, the most common being allergic and nonallergic nasal hyperreactivity and septal deviation.²

When standard medical treatment fails, patients often benefit from surgical reduction of the inferior turbinates. A number of surgical treatments are available for the treatment of nasal obstruction secondary to inferior turbinate hypertrophy, including total or partial turbinectomy, turbino-

plasty, submucosal resection, laser-assisted turbinoplasty, cryosurgery, argon plasma surgery, corticosteroid injections, electrocautery with monopolar and bipolar techniques, and radiofrequency (RF) volumetric tissue reduction.³⁻⁵ All of these techniques have potential complications. The goal of the procedure should



CME available online at
www.jamaarchivescme.com
and questions on page 737

be an optimal volume reduction to diminish complaints while preserving physiologic function. However, the variety of surgical methods used indicates a lack of consensus regarding the optimal technique to apply.³⁻⁵

Currently, RF or high-frequency (HF) tissue reduction and electrocautery are commonly used procedures for turbinate reduction. These 3 techniques provide satisfactory results, but adverse events are frequently observed. Inferior partial turbinotomy is an accepted treatment for turbinate hypertrophy, giving considerable improvement in the nasal airway. Various articles have been published, some favoring and some against the procedure.³⁻⁵ The aims of this study were to compare the efficacy of RF, HR, and electrocautery treatments with partial inferior turbinotomy in the treatment of nasal obstruction caused by inferior turbinate hypertrophy and to evaluate their microscopic and macroscopic effects on the nasal mucosa and physiologic function through evaluation of nasal mucociliary transport time (NMTT) and pressure sensation via the nasal monofilament test.

METHODS

STUDY GROUP

The regional ethics committee approved the study protocol. Informed written consent was obtained from all participants. Eighty patients, aged between 19 and 68 years (52 men and 38 women) were enrolled in this nonrandomized study and divided into 4 numerically equal groups. All patients had nasal obstruction due to turbinate hypertrophy that was refractory to medical therapy (topical corticosteroids) for at least 3 months.

Patients with previous turbinate surgery, significant septal deviation, septal perforation, alar collapse, middle turbinate disease (hypertrophy or concha media bullosa), nasal polyps or tumors, nasal radiotherapy, recurrent sinusitis, or allergic rhinitis were excluded. Additional exclusion criteria included oral steroid use, genetic disorders accompanied by ciliary dysfunction, smokers, coagulation disorders, uncontrolled hypertension, presence of a cardiac pacemaker, and anosmia.

SURGICAL PROCEDURE

In groups A, B, and C, the respective RF, HF, and electrocautery procedures were performed under local anesthesia and endoscopic guidance. Ten minutes before treatment, cotton soaked with lidocaine, 1%, solution was introduced into each inferior meatus.

In group A, RF was delivered by the ENT Coblator Plasma Surgery System (Celon, Teltow bei Berlin, Germany). The coblation controller unit was set to a power between 4 and 5 (maximum power in this machine). The needle of the probe was inserted submucosally in the inferior half of the turbinate, longitudinally. The number of passes done in each turbinate was based on the degree of turbinate hypertrophy.

Group B patients underwent surgical treatment by HF programmed bipolar diathermocoagulation (Timed TD 50; Micropulse AIRD, Genoa, Italy). The diathermocoagulation of the inferior turbinates was performed by drawing the electrode along the tail, body, and head of the inferior turbinates.

Group C underwent superficial electrocautery of the inferior turbinate. Electrocautery was performed by a straight tip electrode at a constant power of 40 to 60 W (Telea-Vesalius, Vicenza, Italy). The electrode was drawn forward on the mucosa of the inferior turbinates.

Under general anesthesia, the patients in group D underwent partial inferior turbinotomy through the excision of redundant mucosa of the turbinates by a scissors at the level of

Table 1. Monofilament Size and Amount of Force Exerted

Fiber Label	Monofilament Size, mm	Force, mg
A	1.65	4.47
B	2.36	22.90
C	2.44	27.50
D	2.83	67.60
E	3.22	166.00
F	3.61	407.40
G	3.84	691.80
H	4.08	1202.30
I	4.17	1479.10
J	4.31	2052.00
K	4.56	3632.00
L	4.74	5500.00
M	4.93	8650.00
N	5.07	11 700.00
O	5.18	15 000.00
P	5.46	29 000.00
Q	5.88	75 000.00
R	6.10	127 000.00
S	6.45	281 500.00
T	6.65	447 000.00

the turbinate hypertrophy (anterior, posterior, and/or total); the resection was limited to the soft tissue. After the operation, a nasal pack was applied for 48 hours.

Postoperatively, all patients received cephalosporin antibiotic therapy for 5 days.

EVALUATION

We evaluated all patients before the procedures and at 7-day and 2-month follow-up visits. Patients were instructed to refrain from using oral or topical steroids, antihistamines, and decongestants during the follow-up period.

A standard visual analog scale (VAS) ranging from 0 (no symptoms, satisfied with the situation) to 10 (the most severe symptoms, dissatisfied) was used to assess subjective symptoms including nasal obstruction, sneezing, itchy nose, hyposmia, headache, snoring, perioperative pain, and patient satisfaction. Objective evaluation of the intranasal findings was performed by anterior rhinoscopy and nasal endoscopy (rigid and flexible). Turbinate edema, secretions, and crusts were graded by a surgeon not involved in the treatment of these patients using a 5-point scale (0, absent; 1, mild; 2, moderate; 3, severe; and 4, very severe).

A set of 20 Semmes-Weinstein monofilaments (Sammons Preston, ABOcare srl, Grugliasco, Turin, Italy) was used to detect nasal sensitivity for both nasal cavities. During the test, nostrils were held open, the vibrissae were held back with a nasal speculum, and patients were told to close their eyes.⁶ The anterior aspect of the inferior turbinates was then probed with a series of 38-mm-long monofilaments of increasing diameters, ranging from 1.65 mm (A) to 6.65 mm (T), and sized and numbered according to increasing force. The monofilaments were labeled with logarithmic Von Frey values ($10 \times$ force in milligrams). The lowest force exerted by the series of monofilaments was 4.47 mg, and the highest was 447 g. Since the instrument markings were Von Frey numbers, representing logarithmic values, they were first converted to force values for statistical testing (**Table 1**) (**Figure 1**).

The examiner kept the filament perpendicular to the test site. The filament was bowed within about 1.5 seconds; the bow was maintained for approximately 1.5 seconds; and the fila-

VISUAL ANALOG SCALE

According to VAS scores, group D patients experienced the most rapid and intense symptom relief. After only 1 week, these patients reported significant symptom improvement ($P = .001$), which was more intense than maximum improvements reported by any other group, even at later dates (**Table 2**).

All groups reported at least moderate symptom improvement after 1 week, but only the improvement in group D reached statistical significance at that time. Both groups A and D reported significant improvement at 2 months, but even the initial improvement in group D at 1 week was greater than that seen in any other group at 2 months (Table 2).

OBJECTIVE EVALUATION
OF INTRANASAL FINDINGS

No synechiae or uncontrolled bleeding were observed in any patients. Significant increases in turbinate edema, secretion, and crusts were observed in groups A, B, and C at the 7-day postsurgical evaluation ($P < .001$ for all), while group D showed significant postoperative reductions of these criteria. Significant improvement was observed in all groups by 2 months after surgery ($P < .001$ for all), with maximum and most rapid improvements observed in group D (Table 2).

MONOFILAMENT TEST

For the stimulus of touch alone, patients treated by partial turbinotomy (group D) required a significantly lower stimulus to trigger a touch response than all other groups, both 7 days ($P = .001$) and 2 months after treatment ($P = .001$): after 7 days, a mean (SD) of 884.0 (0.18) mg following turbinotomy vs 956.4 (0.54) mg following RF; 957.3 (0.63) mg following HF; and 1072.0 (0.06) mg following electrocautery. After 2 months, the mean pressure required was 278.5 (0.10) mg following turbinotomy vs 481.0 (0.24) mg following RF; 471.9 (0.18) mg following HF; and 494.8 (0.03) mg following electrocautery (**Table 3**).

NASAL MUCOCILIARY TRANSPORT TIME

Normal mean (SD) NMTT was observed after 7 days (14.31 [1.59] minutes) and 2 months (14.25 [2.10] minutes) in group D. However, the NMTT of all other groups showed less favorable results, with significant postoperative increases at both 7 days and 2 months ($P < .05$ for all comparisons) (Table 3). In group A, the NMTT increased from a mean (SD) preoperative time of 14.30 (2.14) minutes to a 7-day postoperative time of 17.13 (2.34) minutes and 16.10 (2.34) minutes after 2 months. In group B, the mean (SD) 2-month NMTT assessment was recorded as 16.28 (2.38) minutes vs a preoperative time of 14.01 (2.03) minutes and 16.58 (2.43) minutes after 7 days. In group C, the mean (SD) preoperative NMTT was




Figure 1. Monofilament assessment. Monofilament used in this study.

ment was removed after an additional 1.5 seconds. The sensitivity threshold was recorded as the minimum monofilament size that patients could detect at least 2 of 3 stimuli from. The minimum filament size at which irritation was caused was also noted. Irritation was defined as discomfort, sneezing, eye tearing, or pain.⁶ For each stimulus, the amount of force in milligrams exerted by the monofilament, as determined by its size, was calculated. The 2.83 filament (67.6 mg) is considered to represent normal sensitivity in most areas of the body and was therefore presented first (Table 1) (Figure 1).

The NMTT was evaluated by the saccharin test after surgery. Saccharin transit time was measured after depositing 15 mg of sodium saccharin, 2%, behind the anterior margin of the inferior turbinate. Patients were instructed to sit with their heads inclined forward at an angle of 10°, swallow every 30 seconds, and avoid breathing through the nose. The saccharine test was the final test used to evaluate patients.⁷

Anterior active rhinomanometry (Rhinomanometer SR 2000; Medtronic AIRD, Genoa, Italy) was performed according to the International Committee for the Standardization of Rhinomanometry guidelines. The flow was evaluated at a transnasal pressure of 150 Pa.⁸

Specimens were taken from the anterior, middle, and posterior portions of the inferior turbinate mucosa, fixed in 10% formaldehyde, and embedded in paraffin. Histologic evaluation was performed of the nasal turbinate mucosa before and 2 months after the procedure.

Statistical analysis was performed by a specialized company using the statistical software package SPSS for Windows, version 9.0 (SPSS Inc, Chicago, Illinois). The *t* test and Wilcoxon signed rank test were used, and *P* values less than .05 were considered statistically significant.

Table 2. Subjective Visual Analog and Objective Evaluation Scores^a

Patient Group	Preoperative	7-Day Follow-up	P Value ^b	2-Month Follow-up	P Value ^c
Subjective Visual Analog Scale (0-10)					
A	7.6 (1.23)	6.9 (1.19)	.99	5.2 (0.98)	.001
B	7.9 (1.31)	7.1 (1.18)	.99	6.4 (1.08)	.99
C	7.8 (1.29)	7.2 (1.22)	.99	6.9 (1.14)	.99
D	7.9 (1.31)	4.3 (0.71)	.001	3.6 (0.67)	.001
Scale of Objective Evaluation (0-4)					
A	2.6 (0.43)	3.5 (0.34)	.001	1.9 (0.41)	.001
B	2.6 (0.38)	3.4 (0.35)	.001	1.7 (0.34)	.001
C	2.7 (0.39)	3.6 (0.38)	.001	1.8 (0.36)	.001
D	2.8 (0.43)	1.9 (0.31)	.001	1.1 (0.31)	.001

^aUnless otherwise noted, data are reported as mean (SD) scores.

^bComparing preoperative with 7-day follow-up scores.

^cComparing preoperative with 2-month follow-up scores.

Table 3. Results of Monofilament Testing, NMTT, and Total Nasal Resistance^a

Patient Group	Preoperative	7-Day Follow-up	P Value ^b	2-Month Follow-up	P Value ^c
Monofilament Testing, Minimum Irritating Force, mg					
A	103.3 (0.15)	956.4 (0.54)	.001	481.0 (0.24)	.001
B	107.4 (0.34)	957.3 (0.63)	.001	471.9 (0.18)	.001
C	67.7 (0.03)	1072.0 (0.06)	.001	494.8 (0.03)	.001
D	59.5 (0.06)	884.0 (0.18)	.001	278.5 (0.10)	.001
NMTT, min					
A	14.30 (2.14)	17.13 (2.34)	.001	16.10 (2.34)	.001
B	14.01 (2.03)	16.58 (2.43)	.001	16.28 (2.38)	.001
C	14.10 (2.06)	17.54 (2.28)	.001	17.18 (2.43)	.001
D	14.15 (2.09)	14.31 (1.59)	.99	14.25 (2.10)	.99
Anterior Active Rhinomanometry, Pa/cm³					
A	1.32 (0.56)	1.08 (0.45)	.99	0.25 (0.02)	.001
B	1.24 (0.76)	1.12 (0.49)	.99	0.26 (0.01)	.001
C	1.19 (0.71)	0.91 (0.39)	.99	0.24 (0.03)	.001
D	1.28 (0.64)	0.24 (0.01)	.001	0.25 (0.01)	.001

Abbreviation: NMTT, nasal mucociliary transport time.

^aUnless otherwise noted, data are reported as mean (SD) values.

^bComparing preoperative with 7-day follow-up values.

^cComparing preoperative with 2-month follow-up values.

14.10 (2.06) minutes vs a 7-day postoperative time of 17.54 (2.28) minutes and 17.18 (2.43) minutes after 2 months.

RHINOMANOMETRY

Both left and right rhinomanometric measures showed a significant nasal flow decrease 7 days after surgery in group D ($P=.001$). Two months after surgery, the rhinomanometric results were significantly improved in all groups ($P<.001$ for all comparisons), at which time there were no significant differences among the 4 groups ($P\geq.99$ for all comparisons) (Table 3).

HISTOLOGIC EVALUATION

Two months after surgery, the histologic analysis of group A patients showed that 14 patients had mucosal edema (70%), and 17 had plasmorrhagy (85%) (Figure 2). In group B, 15 patients had diffuse metaplastic modifica-

tions of the nasal mucosa (75%) (Figure 3). In group C, examinations revealed that 16 patients had deep mucosal modification, granulocyte infiltration, and squamocellular metaplasia (80%) (Figure 4). All of the postoperative specimens of group D patients were normal compared with the preoperative histologic analysis (Figure 5).

COMMENT

The goal of turbinate surgery is to obtain an improvement in nasal breathing while preserving the physiologic function of the turbinate and minimizing discomfort and other adverse effects. No technique is perfect, and each is associated with known short- and long-term complications, such as bleeding and atrophic rhinitis. The variety of surgical techniques available highlights the absence of consensus regarding the optimal technique.^{5,9,10}

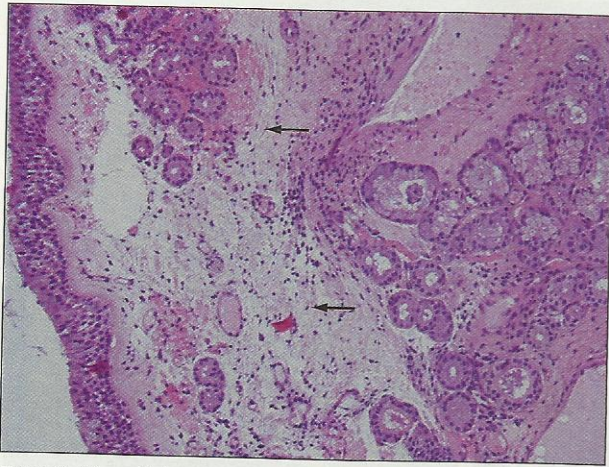


Figure 2. After radiofrequency treatment. Mucosal edema and plasmorrhagy (arrows) are apparent (hematoxylin-eosin, original magnification $\times 20$).

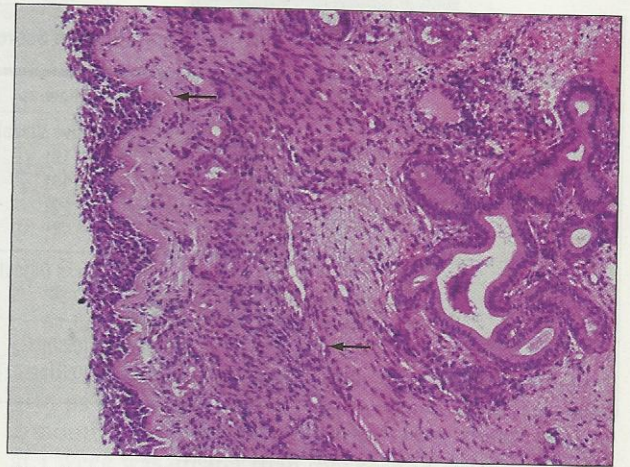


Figure 4. After electrocautery treatment. Deep mucosal modifications with granulocyte infiltration and squamocellular metaplasia are apparent (arrows) (hematoxylin-eosin, original magnification $\times 20$).

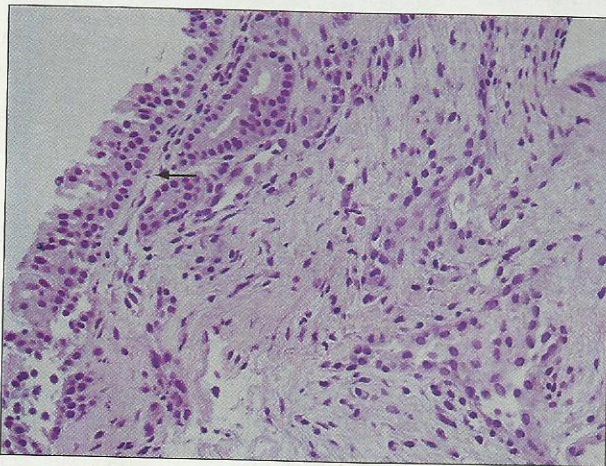


Figure 3. After high-frequency treatment. Diffuse metaplastic modifications of the nasal mucosa are apparent (arrow) (hematoxylin-eosin, original magnification $\times 40$).

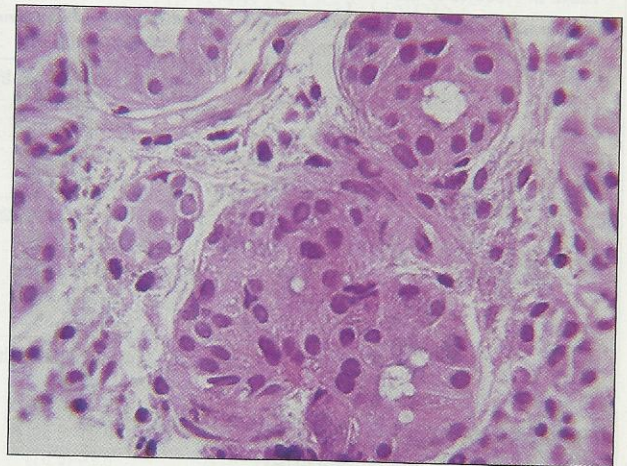


Figure 5. After partial turbinotomy. Nasal mucosa appears normal (hematoxylin-eosin, original magnification $\times 60$).

The primary controversy in inferior turbinate surgery revolves around inferior turbinectomy and the speculated risk of atrophic rhinitis and permanent mucosal damage. Studies of several large series of inferior turbinectomies have not demonstrated evidence of associated rhinitis sicca or atrophic rhinitis complications.¹¹ However, concern over this potential complication, which can be devastating, remains and is used by many as an argument for a more conservative surgical approach.¹⁰

Continued development of new techniques such as RF, HF, and electrocautery reduction techniques has added to the available armamentarium for treating mucosal turbinate hypertrophy. In recent years, these techniques have become popular, and many authors describe their effectiveness.^{5,9,10} All of these electrosurgical techniques use electricity to damage turbinate tissue, but they differ in the control and delivery of energy.^{9,12,13}

Radiofrequency volumetric tissue reduction creates ionic agitation in the tissue, inducing submucosal necrosis. The resultant fibrosis of the submucosa adheres the mucosa to the turbinate periosteum, reducing the blood flow to the turbinate. Resultant wound contraction causes volume reduction of the inferior turbinate

without damage to the overlying mucosa. The target temperature can be controlled at 60°C to 90°C to prevent surrounding tissue damage.^{5,9}

High-frequency programmed bipolar decongestion involves passing a bipolar electrode over the lower turbinate. The procedure creates an area of coagulative necrosis that after 30 days is replaced by a sclerotic connective tissue that decreases the size of the hypertrophic turbinate.¹²

Electrocautery can be performed with either linear mucosal or submucosal contact. For surface cautery, a wire or needle electrode can be used to streak the turbinate mucosal surface. Submucosal cautery can be performed with either a unipolar or bipolar electrode to induce fibrosis and wound contracture and resultant volume reduction. The unipolar approach coagulates tissue circumferentially around the electrode, while the bipolar technique produces coagulation necrosis between the needle electrodes. High tissue temperatures (up to 800°C) can be achieved. This leads to significant surrounding tissue injury and damage to the overlying mucosa.¹³

In summary, all of these "hot" surgical techniques cause submucosal damage and necrosis while improving res-

piration, and most of them do not take the nasal function into consideration. In fact, these so-called conservative techniques work on submucosal tissue rich in nerve fibers and damage the receptor nerve complex covering the nasal mucosa, notably provoking denervation and resulting in nasal hyporeactivity. Moreover, they do not supplant surgical resection when indicated and have shown poorer long-term outcomes: several months after these hot surgical procedures, patients have presented with multiple negative symptoms, including nasal obstruction and crusts.^{5,12} Our VAS and objective evaluation scale intranasal findings confirm this evidence against the use of these hot surgical techniques (Table 2 and Table 3).

Our results also highlight the thermal damage of the nasal mucosa in a high percentage of patients treated with RF, HF, and electrocautery, as demonstrated by the presence of submucous granulocyte infiltration, diffuse metaplastic modifications, and plasmorrhagy. These data show that too much heat can damage the turbinate mucosa and cause it to become chronically inflamed.

The data also show a significant hyposensitization of nasal mucosa in patients treated with hot methods, as measured by the monofilament testing devices, which are standard means for repeatable testing and measurement of the sensitivity threshold. One study has suggested that monofilaments may be a useful tool to assess nasal sensitivity and reactivity.⁶ The collection of fibers beneath the epithelium is composed of mainly sensory fibers but also some autonomic fibers. Most of the fibers in the region of glands and blood vessels are secretomotor fibers, but sensory fibers are known to also innervate these structures. Sensory fibers may contribute to a hyperresponsive or hyporesponsive state, and secretomotor fibers contribute to congestion and rhinorrhea.^{6,14}

An inverse relationship exists between the number of functional subepithelial nerve fibers and the stimulus strength required to detect the stimuli: when some of the fibers are damaged, patients will become less sensitive to touch.⁶ This explains why a touch sensation that would be detected by healthy subjects was not perceived by our patients who were treated with RF, HF, or electrocautery methods (ie, their nasal mucosa had become hyporesponsive). It also explains why stimuli perceived by patients who underwent treatment with these hot techniques were not perceived with the same intensity as they would be by healthy subjects. Most importantly, it explains why after turbinotomy, patients had normal sensitivity, while the patients who underwent the hot treatments had a higher pressure threshold (ie, hyporesponsive nasal mucosa). The hyporesponsive nasal mucosa showed a devitalization of nervous nasal fibers after RF, HF, and electrocautery. Our data show that the blockage of the trigeminal sensorial receptors (afferent branch), and consequently the inhibition of the parasympathetic system (efferent branch), produces a reduction in tactile sensitivity. Monofilament testing has become the standard means for repeatable testing and measurement of the threshold of mucosal sensory perception.⁶

Clinical studies with long-term follow-up show that RF, HF, and electrocautery techniques are ineffective when patients have an enlarged turbinate bone, a con-

dition occurring in about 10% to 15% of patients with obstruction.^{4,5} The same studies highlight partial inferior turbinotomy as an effective technique to reduce an enlarged turbinate bone without important adverse effects.^{4,5,10,11,15}

The present study shows that turbinotomy is highly effective in preserving mucociliary function, particularly compared with the other surgical procedures at 2-month postoperative follow-up. The normalization of nasal mucociliary clearance seen 2 months after surgery is a sign of the reversible damage of the nasal mucosa and may indicate that turbinotomy causes no observable loss of function of the nasal mucosa. The average NMTT increased in all the other procedures, indicating sustained thermal damage.

The term *hot procedures* can be used to describe RF, HR, and electrocautery procedures. The important adverse effects of these techniques are likely the consequence of the heat generated by the power applied. In accordance with other studies, our data show several disadvantages of these applications: limited reduction in turbinate size (limited by the size of the lesion created by the RF application), poor long-term results (may require repeated procedures), and higher rate of complications (eg, crusting, pain, hyporesponsivity of nasal mucosa).⁵

Although inferior turbinotomy presents some disadvantages, such as necessitating general anesthesia and nasal packing, in the present study, we show that this surgical method is the most effective in improving nasal obstruction and related nasal symptoms. The advantages of turbinotomy can be listed as follows: it preserves the nasal epithelium without changing mucociliary function or increasing secretions; patients do not develop crusts; and overall, the procedure results in no changes in nasal sensitivity or nasal mucosa and submucosa (eg, metaplasia, plasmorrhagia) because the surgery preserves the function of the complex neuroreceptor network covering the nasal mucosa.

In conclusion, partial inferior turbinotomy, when compared with other "pseudoconservative" techniques (RF, HF, and electrocautery treatments), was found to be a superior, more efficient, and noninvasive method for the treatment of chronic turbinate hypertrophy unresponsive to prior medical treatment. This surgical method allows for optimal and complete resolution of nasal obstruction without impairing nasal physiologic characteristics. Our results remove all doubts about its efficacy and show that partial inferior turbinotomy clearly preserves nasal physiologic characteristics better than the other techniques evaluated in this investigation.

Submitted for Publication: September 15, 2008; final revision received January 5, 2009; accepted January 11, 2009.

Correspondence: Renzo Mora, MD, Via dei Mille 11/9, 16147, Genoa, Italy (renzomora@libero.it).

Author Contributions: Dr Mora had full access to all the data in the study and takes responsibility for the integrity of the data and the accuracy of the data analysis. *Study concept and design:* F.-A. Salzano. *Acquisition of data:* Dellepiane, Zannis, and G. Salzano. *Analysis and interpreta-*

tion of data: Mora, Moran, and Salami. *Drafting of the manuscript*: Mora, Dellepiane, Zannis, G. Salzano, and Moran. *Critical revision of the manuscript for important intellectual content*: F.-A. Salzano and Salami. *Statistical analysis*: Mora, Zannis, and G. Salzano. *Study supervision*: F.-A. Salzano, Dellepiane, Moran, and Salami. **Financial Disclosure**: None reported.

REFERENCES

1. Passali D, Bellussi L, Damiani V, Passali GC, Passali FM, Celestino D. Allergic rhinitis in Italy: epidemiology and definition of most commonly used diagnostic and therapeutic modalities. *Acta Otorhinolaryngol Ital*. 2003;23(4):257-264.
2. Bäck LJ, Hytönen ML, Malmberg HO, Ylikoski JS. Submucosal bipolar radiofrequency thermal ablation of inferior turbinates: a long-term follow-up with subjective and objective assessment. *Laryngoscope*. 2002;112(10):1806-1812.
3. Jackson LE, Koch RJ. Controversies in the management of inferior turbinate hypertrophy: a comprehensive review. *Plast Reconstr Surg*. 1999;103(1):300-312.
4. Segal S, Eviatar E, Berenholz L, Kessler A, Shlamkovitch N. Inferior turbinectomy in children. *Am J Rhinol*. 2003;17(2):69-73.
5. Sapci T, Sahin B, Karavus A, Akbulut UG. Comparison of the effects of radiofrequency tissue ablation, CO2 laser ablation, and partial turbinectomy applications on nasal mucociliary functions. *Laryngoscope*. 2003;113(3):514-519.
6. O'Hanlon S, Facer P, Simpson KD, Sandhu G, Saleh HA, Anand P. Neuronal markers in allergic rhinitis: expression and correlation with sensory testing. *Laryngoscope*. 2007;117(9):1519-1527.
7. Clement PA. Committee report on standardization of rhinomanometry. *Rhinology*. 1984;22(3):151-155.
8. Salzano FA, Manola M, Tricarico D, Precone D, Motta G. Mucociliary clearance after aerobic exertion in athletes. *Acta Otorhinolaryngol Ital*. 2000;20(3):171-176.
9. Sapci T, Usta C, Evcimik MF, et al. Evaluation of radiofrequency thermal ablation results in inferior turbinate hypertrophies by magnetic resonance imaging. *Laryngoscope*. 2007;117(4):623-627.
10. Passali D, Passali FM, Damiani V, Passali GC, Bellussi L. Treatment of inferior turbinate hypertrophy: a randomized clinical trial. *Ann Otol Rhinol Laryngol*. 2003;112(8):683-688.
11. Salzano FA, Iovine R, Dispenza F, Ferrara S, Sciandra D, Motta G. Inferior turbinate surgery. In: Pappaspyrou S, ed. *International Proceedings of the 5th European Congress of Oto-Rhino-Laryngology Head and Neck Surgery (EUFOS)*. Bologna, Italy: Medimond Srl; 2004:197-199.
12. Kafle P, Maharjan M, Shrestha S, Toran KC. Comparison of sub mucosal diathermy and partial resection of inferior turbinate in the treatment of symptomatic nasal valve blockage. *Kathmandu Univ Med J (KUMJ)*. 2007;5(4):501-503.
13. Herzog M, Schmidt A, Metz T, et al. Pseudoaneurysm of the lingual artery after temperature-controlled radiofrequency tongue base reduction: a severe complication. *Laryngoscope*. 2006;116(4):665-667.
14. McKeegan DE, Demmers TG, Wathes CM, Jones RB, Gentle MJ. Response characteristics of nasal trigeminal nociceptors in Gallus domesticus. *Neuroreport*. 2002;13(8):1033-1035.
15. Farmer SE, Eccles R. Understanding submucosal electrosurgery for the treatment of nasal turbinate enlargement. *J Laryngol Otol*. 2007;121(7):615-622.